

European Society of Endodontology position statement: External Cervical Resorption



European Society of Endodontology (ESE) developed by:

S. Patel^{1,2}, P. Lambrechts³, H. Shemesh⁴ & A. Mavridou³

¹Endodontic Postgraduate Unit, King's College London Dental Institute, London; ²Private Practice, 45 Wimpole Street, London, UK; ³Conservative Dentistry, KU Leuven, Leuven, Belgium; and ⁴Academic Center for Dentistry Amsterdam (ACTA), Amsterdam, The Netherlands

Abstract

European Society of Endodontology (ESE) developed by: Patel S, Lambrechts P, Shemesh H, Mavridou A. European Society of Endodontology position statement: External Cervical Resorption. *International Endodontic Journal*, **51**, 1323–1326, 2018.

This Position Statement represents the consensus of an expert committee convened by the European Society of Endodontology (ESE) on External Cervical Resorption (ECR). The statement is based on current clinical and scientific evidence as well as the expertise of the committee. The primary aim is to provide a current authoritative position on the aetiology,

histopathology, clinical presentation and management of ECR, and also to highlight areas where there is minimal evidence. Previously published review articles provide more detailed background information and the basis for this position statement (*International Endodontic Journal* **51**, 1205, 2018, *International Endodontic Journal* **51**, 1224, 2018). It is intended that this position statement will be updated at appropriate intervals, as further evidence emerges.

Keywords: CBCT, endodontology, external cervical resorption, guidelines.

Received 27 August 2018; accepted 27 August 2018

Introduction

External Cervical Resorption (ECR) usually starts in the cervical region of the affected tooth and initially involves only the periodontal ligament, cementum and dentine. However, in advanced stages the pulpal tissues may also become involved (Luso & Luder 2012, Mavridou *et al.* 2016a, Patel & Saberi 2018).

Until recently, the majority of the literature on this topic has been individual case (series) reports focusing either on the possible aetiology and/or treatment options. Literature on histopathology and diagnosis is limited (Mavridou *et al.* 2017a,b) contributing to the risk of inappropriate diagnosis and suboptimal management (Patel *et al.* 2018a,b).

Aetiology

For ECR to occur and propagate, it is assumed that there must be damage to the periodontal ligament (PDL) and cementum, in combination with a stimulating factor that can induce and maintain the activity of clastic cells (Mavridou *et al.* 2017a,b). The aetiology of ECR is poorly understood, and there may be aetiological factors which have not yet been identified. Previous history of dental trauma

Further contributions and revisions were made by ESE Executive Board members: PMH Dummer, H Duncan, V Franco D Ørstavik, L Tjäderhane, J Whitworth.

Correspondence: Paul M. H. Dummer, CEO of the European Society of Endodontology, Postboks 1237 Vika, 0110 Oslo, Norway (e-mail: ceo@e-s-e.eu).

and/or orthodontic treatment are the factors most commonly associated with ECR (Tronstad 1988, Heithersay 1999, Mavridou *et al.* 2017a,b). However, more research is required to confirm the cause and effect relationship of these suggested aetiological factors (Patel *et al.* 2018a).

Histopathogenesis

It is well established that ECR is a complex and dynamic process (Luso & Luder 2012, Mavridou *et al.* 2016a, 2017b), consisting of three main stages; resorptive (initiation), resorptive (propagation) and reparative (remodelling) (Mavridou *et al.* 2016a, 2017b). Resorption and repair can occur in parallel in different areas of the same lesion. Increased understanding of the pathophysiology may ultimately result in strategies to prevent and/or control the disease process.

Clinical presentation

The most commonly affected teeth are maxillary incisors, canines, first molars and mandibular first molars (Mavridou *et al.* 2017a).

The presenting features of ECR are highly variable and dependent on several factors including location and degree of progression (Patel *et al.* 2018a). It commonly presents as an incidental finding on clinical and radiographic examination, though there may be clinical signs of localized gingival inflammation and bleeding, pulpal involvement, or in more advanced cases apical periodontitis (Bergmans *et al.* 2002, Patel *et al.* 2009a, Bhuva *et al.* 2011).

Highly vascularized lesions involving the supracoronal regions of teeth may appear as pink spots, though other lesions such as advanced areas of internal resorption extending into supragingival tissues may also present in this way. ECR may also be mistaken clinically and radiographically for cervical caries. However, high-quality evidence on the clinical presentation of ECR, as well as on its rate of progression, is lacking.

Radiographic assessment

There is no 'classic' radiographic appearance of ECR. The lesions may be radiolucent (resorptive phase), radiopaque (reparative phase) or present as a combination of both depending on the stage of the lesion. To differentiate ECR from internal inflammatory resorption, the outline of the root canal walls should be traceable through the lesion on periapical radiographs. The parallax imaging technique can be used

to distinguish ECR from internal resorption as well as confirming the location of ECR lesions which are not detectable clinically by probing.

The limitations of periapical radiographs are well documented (Bender & Seltzer 1961, Patel *et al.* 2009b), and can result in misdiagnosis and/or poor management of ECR (Schwartz *et al.* 2010, Gunst *et al.* 2013, Vaz de Souza *et al.* 2017).

CBCT overcomes the limitations of periapical radiographs (Abella *et al.* 2012, Hashem *et al.* 2013, Rodriguez *et al.* 2017a,b) and can improve the diagnosis and/or management of ECR, by giving the clinician a precise appreciation of the nature and extent of the lesion; its 3D morphology, degree of circumferential spread and proximity to the root canal (Mavridou *et al.* 2016b, Patel *et al.* 2016, Patel *et al.* 2018b).

The European Society of Endodontology position statement on CBCT (ESE 2014) highlights the relevance of CBCT for the management of potentially restorable ECR lesions. The radiation dose of a small field of view CBCT scan is relatively low when compared to computed tomography and is in the same order of magnitude as multiple parallax radiographs (Loubele *et al.* 2012, Pauwels *et al.* 2012); this justifies its use for ECR diagnosis and follow-up. CBCT is recommended when the diagnosis is unclear, and/or treatment is being planned for ECR.

The Heithersay classification of ECR is based on two-dimensional imaging, resulting in underestimation and/or inadequate appreciation of the true extent of the resorptive process (Heithersay 1999, Vaz de Souza *et al.* 2017). The Patel classification is three-dimensional, based on periapical radiographs and CBCT (Patel *et al.* 2018b). The aim of this descriptive classification is to ensure an accurate diagnosis and aid communication between clinicians. In the future, it should allow objective outcome assessment, and aid in decision making and formulating a treatment plan that is likely to be successful (Fig. 1). Ultimately, treatment outcome and prognostic factors may also be assessed in relation to the three-dimensional nature of ECR (Patel *et al.* 2018b).

As with any device emitting ionizing radiation, the benefits of the CBCT scan must outweigh the risks (ICRP 2007, ESE 2014). The ALARA principle ('as low as reasonably achievable') must be applied.

Treatment

The aim of treatment is to retain affected teeth in a healthy and functional state and, when indicated, improve aesthetics (Patel *et al.* 2018c).

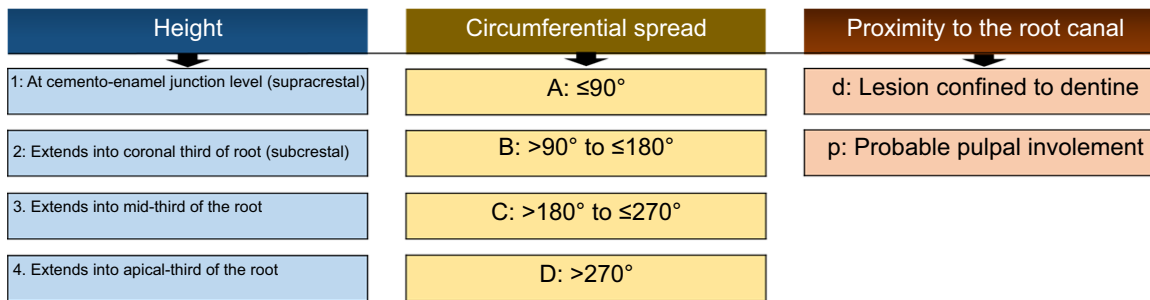


Figure 1 A three-dimensional classification for ECR (Patel *et al.* 2018c).

Table 1 Treatment options for ECR

External repair of the resorptive defect \pm endodontic treatment
Internal repair and root canal treatment
Intentional replantation
Periodic review (untreatable teeth)
Extraction (untreatable teeth)

The objectives of treatment are elimination of the resorptive tissue, sealing of the resultant defect and portal of entry and prevention of recurrence.

Treatment options for ECR depend on the extent, nature and accessibility of the resorptive process; in some cases it may be necessary to raise a mucoperiosteal flap. The treatment options include (Table 1):

- *External repair of the resorptive defect \pm endodontic treatment*
Excavation of the resorptive defect and restoration of the defect with a direct restoration, for example Patel class 1Ad, 2Ad, 2Bd. Root canal treatment may be indicated if there is (probable) pulp involvement, for example Patel class 1Ap, 2Ap, 2Bp.
- *Internal repair and root canal treatment*
Root canal treatment, excavation and restoration of the resorptive defect with a direct plastic restoration, for example Patel class 2Cp, 2Dp, 3Cp, 3Dp.
- *Intentional replantation*
Extraction of an endodontically treated tooth to allow restoration and/or recontouring of an otherwise inaccessible ECR defect, followed by reinsertion, for example Patel class 3Ad, 3Bd.
- *Periodic review*
Untreatable teeth may be reviewed on a periodic basis, for example Patel class 2-4Dd, 2-4Dp.
- *Extraction*
Indicated when ECR is inaccessible for treatment, or when the lesion is so extensive that the tooth may not be restored to satisfactory function or aesthetics.

More research is required to assess the impact of these management options on the outcome of treatment, as well as prognostic factors which may impact on the survival rate of affected teeth.

Prognosis

External Cervical Resorption lesions that are accessible and therefore amenable to conservative treatment have a good prognosis. However, patients should be advised of the limited evidence on treatment outcomes. Research is required to assess the impact of the size and stage of the lesion (resorptive versus reparative) on the outcome of treatment.

Conclusion

The clinical and radiographic presentation of ECR is highly variable with no classic presentation. The current evidence confirms that periapical radiography has significant limitations in accurately assessing the extent and nature of ECR and formulating an appropriate treatment plan. Therefore, CBCT is recommended when considering treatment of potentially treatable ECR lesions. Further high-quality research is required to support the evidence base in all aspects of ECR from its pathophysiology to effective clinical management.

References

- Abella F, Patel S, Durán-Sindreu F, Mercadé M, Roig M (2012) Mandibular first molars with disto-lingual roots: review and clinical management. *International Endodontic Journal* **45**, 963–78.
- Bender IB, Seltzer S (1961) Roentgenographic and direct observation of experimental lesions in bone: I. *Journal of the American Dental Association* **62**, 152–60.
- Bergmans L, Van Cleynenbreugel J, Verbeken E, Wevers M, Van Meerbeek B, Lambrechts P (2002) Cervical external

- root resorption in vital teeth, X-ray microfocus-tomographical and histopathological case study. *Journal of Clinical Periodontology* **29**, 580–5.
- Bhuva B, Barnes JJ, Patel S (2011) The use of limited cone beam computed tomography in the diagnosis and management of a case of perforating internal root resorption. *International Endodontic Journal* **44**, 777–86.
- ESE (2014) European Society of Endodontology position statement: the use of CBCT in endodontics. *International Endodontic Journal* **47**, 502–4.
- Gunst V, Mavridou A, Huybrechts B, Van Gorp G, Bergmans L, Lambrechts P (2013) External cervical resorption: an analysis using cone beam and microfocus computed tomography and scanning electron microscopy. *International Endodontic Journal* **46**, 877–87.
- Hashem D, Brown JE, Patel S *et al.* (2013) An *in vitro* comparison of the accuracy of measurements obtained from high- and low-resolution cone-beam computed tomography scans. *Journal of Endodontics* **39**, 394–7.
- Heithersay GS (1999) Clinical, radiologic, and histopathologic features of invasive cervical resorption. *Quintessence International* **30**, 27–37.
- ICRP (2007) Publication 103. The 2007 Recommendations of the international commission on radiological protection. Annals of the International Commission of Radiological Protection 37.
- Loubele M, Bogaerts R, Van Dijck E *et al.* (2012) Comparison between effective radiation dose of CBCT and MSCT scanners for dentomaxillofacial applications. *European Journal of Radiology* **71**, 461–8.
- Luso S, Luder HU (2012) Resorption pattern and radiographic diagnosis of invasive cervical resorption. A correlative microCT, scanning electron and light microscopic evaluation of a case series. *Schweizer Monatsschrift für Zahnmedizin* **122**, 914–30.
- Mavridou AM, Hauben E, Wevers M, Schepers E, Bergmans L, Lambrechts P (2016a) Understanding external cervical resorption in vital teeth. *Journal of Endodontics* **42**, 1737–51.
- Mavridou AM, Pyka G, Kerckhofs G *et al.* (2016b) A novel multimodular methodology to investigate external cervical tooth resorption. *International Endodontic Journal* **49**, 287–300.
- Mavridou AM, Bergmans L, Barendregt D, Lambrechts P (2017a) Descriptive analysis of factors associated with external cervical resorption. *Journal of Endodontics* **43**, 1602–10.
- Mavridou AM, Hauben E, Wevers M, Schepers E, Bergmans L, Lambrechts P (2017b) Understanding external cervical tooth resorption patterns in endodontically treated teeth. *International Endodontic Journal* **12**, 1116–33.
- Patel S, Saberi N (2018) The ins and outs of root resorption. *British Dental Journal* **224**, 691–9.
- Patel S, Kanagasingam S, Ford PT (2009a) External cervical resorption: a review. *Journal of Endodontics* **35**, 616–25.
- Patel S, Dawood A, Whaites E, Pitt Ford T (2009b) New dimensions in endodontic imaging: part 1. Conventional and alternative radiographic systems. *International Endodontic Journal* **42**, 447–62.
- Patel K, Mannocci F, Patel S (2016) The assessment and management of external cervical resorption with periapical radiographs and cone-beam computed tomography: a clinical study. *Journal of Endodontics* **42**, 1435–40.
- Patel S, Mavridou AM, Lambrechts P, Saberi N (2018a) External cervical resorption-part 1: histopathology, distribution and presentation. *International Endodontic Journal* **51**, 1205–23.
- Patel S, Foschi F, Condon R, Pimentel T, Bhuva B (2018b) External cervical resorption: part 2 - management. *International Endodontic Journal* **51**, 1224–38.
- Patel S, Foschi F, Mannocci F, Patel K (2018c) External cervical resorption: a three-dimensional classification. *International Endodontic Journal* **51**, 206–14.
- Pauwels R, Beinsbergera J, Collaert B *et al.* (2012) Effective dose range for dental cone beam computed tomography scanners. *European Journal of Radiology* **81**, 267–71.
- Rodriguez G, Abella F, Durán-Sindreu F, Patel S, Roig M (2017a) Influence of cone-beam computed tomography in clinical decision making among specialists. *Journal of Endodontics* **43**, 194–9.
- Rodriguez G, Patel S, Durán-Sindreu F, Roig M, Abella F (2017b) Influence of cone-beam computed tomography on endodontic retreatment strategies among general dental practitioners and endodontists. *Journal of Endodontics* **43**, 1433–7.
- Schwartz RS, Robbins JW, Rindler E (2010) Management of invasive cervical resorption: observations from three private practices and a report of three cases. *Journal of Endodontics* **36**, 1721–30.
- Tronstad L (1988) Root resorption - etiology, terminology and clinical manifestations. *Endodontics and Dental Traumatology* **4**, 241–52.
- Vaz de Souza D, Schirru E, Mannocci F, Foschi F, Patel S (2017) External cervical resorption: a comparison of the diagnostic efficacy using 2 different cone-beam computed tomographic units and periapical radiographs. *Journal of Endodontics* **43**, 121–5.